

# Automatic segmentation and classification of fundus eye images for glaucoma diagnosis

Katarzyna Stapor<sup>1</sup>, Lesław Pawlaczyk<sup>1</sup>, Radim Chrástek<sup>2</sup>,  
Heinrich Niemann<sup>2</sup> and Georg Michelson<sup>3</sup>

<sup>1</sup>Institute of Computer Science, Silesian Technical University, Akademicka 16,  
PL-44-100 Gliwice, Poland

<sup>2</sup>Chair for Pattern Recognition, Friedrich-Alexander-University Erlangen-Nuremberg,  
Martensstrasse 3, D-91058 Erlangen, Germany

<sup>3</sup>Department of Ophthalmology, Friedrich-Alexander-University Erlangen-Nuremberg  
Schwabachanlage 6, D-91054 Erlangen, Germany  
Email: delta@ivp.iinf.polsl.gliwice.pl

**Abstract.** In this paper the new method for automatic classification of fundus eye images into normal and glaucomatous ones is proposed. The new, morphological features for quantitative cup evaluation are proposed based on genetic algorithms. For computation of these features the original method for automatic segmentation of the cup contour is proposed. The computed features are then used in classification procedure which is based on multilayer perceptron. The mean sensitivity is 90% while the mean specificity: 86%. The obtained results are encouraging.

## 1 Introduction

Optic disc (the region where the optic nerve leaves resp. enters the eye known as "blind spot") structures evaluation is one of the most important examinations in glaucoma progress monitoring and diagnosis. Glaucomatous changes in retina appearance embrace various changes in neuroretinal rim and cup, as the result of nerve fibers damages. Searching for glaucoma damages during routine examination (i.e. based on ophthalmoscope and slit lamp with Volk lens) is not an easy task and gives uncertain results even with the experienced ophthalmologist [1]. The existing methods of qualitative analysis are very subjective, while quantitative methods of optic disc morphology evaluation (cup to disc ratio, neuroretinal rim area; the cup is a area within the optic disc where no nerve fibers and blood vessels are present and in 3D image appears as an excavation; the neuroretinal rim is the area between optic disc border and cup border) do not result in full diagnosis. The new methods of morphologic analysis based on scanning-laser-tomography are expensive and accessible only in specialized ophthalmic centers. That is why we have developed a more objective and cheaper method that enables automatic classification of digital fundus eye images into normal and glaucomatous ones. The fundus eye images were obtained by classical fundus-camera. We plan to build the proposed methodology into classical fundus-camera software to be used in routine examinations by an ophthalmologist.

## 2 State-of-the-art

In the existing approaches to automatic segmentation of fundus eye images for supporting glaucoma examinations researchers focused on the detection of the optic disc and its characteristics only [2,3,4]. The automatic extraction of the cup region from fundus eye images was not the area of interest. Also, automatic classification of single fundus eye image acquired from fundus cameras into normal and glaucomatous has received no attention.

## 3 Method

### 3.1 Automatic segmentation of the cup contour

Digital fundus eye images are acquired from classical fundus camera in RGB additive color model. The color normalization step using histogram specification [5] is performed to decrease the variation in the color of fundus eye images from different patients. A copy of the acquired fundus eye image is converted into HSV color model. On RGB image blood vessels are detected automatically using a set of contour filters according to a method described in [6].

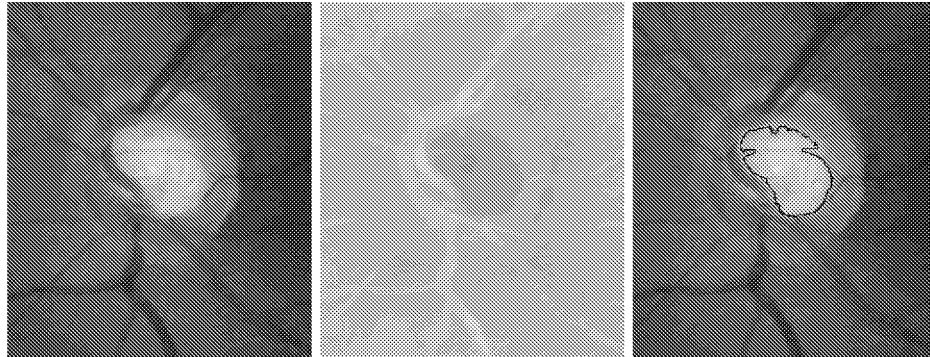
Based on the detected vessels, the averaging of H, S, V components in HSV image is performed to decrease the contrast. All pixels comprising the detected vessels lying inside the user rectangle belong to the subregion named here  $R_{cup-vessels}$ . First, the input image is converted from RGB to HSV color model [5]. By overlying the image with detected vessels on the input, converted image all border pixels of the detected vessels are found (subregion  $R_{cup-vessels}$ ). For each border pixel in  $R_{cup-vessels}$  its new color components  $[H_{avg}, S_{avg}, V_{avg}]$ , being the average of the appropriate components of pixels lying in the 8-connected neighborhood outside of region  $R_{cup-vessels}$  are found. After recalculation of all border pixels, they are deleted, new border pixels are found and the process is repeated until size of  $R_{cup-vessels}$  is higher than 0.

The preprocessed HSV image is converted into L\*a\*b\* color model. Based on our previous experience, only channel a\* is used for further examinations.

Next, the a\* component of L\*a\*b\* image is binarized by the proposed adaptive thresholding method which results in white pixels of the cup (i.e. the object) and black pixels of the rest of the image (i.e. the background). In the adaptive thresholding method a local threshold is found by statistically examining the intensity values of a local neighborhood of each pixel. A window centered at each pixel is constructed as its local neighborhood. The statistic used is a function:

$$T = M_{mean} - C \quad (1)$$

where  $M_{mean}$  is a mean of gray level values in the window, C is a constant, experimentally set. Fig. 2(a) shows the input image, Fig. 2(b) the a\* channel of the input image, while Fig. 2(c) the contour of the segmented cup region overlaid on the input image.

**Fig. 1.** Detection of the cup region

(a) The input image

(b) Channel  $a^*$  of the input image

(c) The contour of the extracted cup region overlaid on the input image

### 3.2 Selection of the cup features using genetic algorithms

Due to nerve fibres damages during glaucoma progress, different changes in a shape of the neuroretinal rim (and of the cup) are observed. In our approach, 30 geometric features including moment invariants [7] and different shape coefficients [7] are computed on the extracted cup region. Genetic algorithms [8] are then used to select the most significant features characterizing the shape of cup region.

In our encoding scheme, the chromosome is a bit string whose length is determined by the number of features (i. e. 30). Each feature is associated with one bit in the string. If the  $i^{th}$  bit is 1 then the  $i^{th}$  feature is selected, otherwise, that component is ignored.

The initial population is generated in the following way: the number of 1's for each chromosome is generated randomly, then, the 1's are randomly scattered in the chromosome.

A population of chromosomes is maintained. Each chromosome is evaluated to determine its "fitness", which determines how likely the chromosome is to survive and breed into next generation. We proposed the following fitness function:

$$Fitness = 10^4 accuracy + 0.4 zeros \quad (2)$$

where *accuracy* is the accuracy rate that the given subset of features achieves (i. e. the performance of a classifier on a given subset of features), *zeros* is the number of zeros in the chromosome.

New chromosomes are created from old chromosomes by the process of cross-over, where parts or two different parent chromosomes are mixed to create the

offspring, and mutation, where the bits of a single parent are randomly perturbed to create a child.

Reproduction is based on a random choice according to a fraction with repetitions method [8].

The following 8 dimensional feature vector has been selected from a set of 30 features by genetic algorithms:

$$(\phi_3, I_1, I_2, I_5, I_7, I_{14}, R_{c2}, W_{sl}) \quad (3)$$

where  $\phi_3$  is Hu invariant moment [7],  $I_1, I_2, I_5, I_7$  and  $I_{14}$  are compound invariant moments [7],  $R_{c2}$  is circular coefficient [7] and  $W_{sl}$  is area to perimeter coefficient.

Hu invariant moment is defined as

$$\phi_3 = (\mu_{30} + 3\mu_{12})^2 + (3\mu_{21} - \mu_{03})^2, \quad \mu_{pq} = \frac{m_{pq}}{(m_{00})^\alpha}, \quad \alpha = \frac{p+q}{2} + 1 \quad (4)$$

where  $\mu_{30}, \mu_{12}, \mu_{21}$  and  $\mu_{03}$  are normalized central moments of order  $(p+q)$  [5].  $m_{pq}$  is spatial central moment of order  $p+q$  defined as [5]:

$$m_{pq} = \sum_{i=1}^M \sum_{j=1}^N (i-I)^p (j-J)^q p(i, j), \quad I = \frac{m_{10}}{m_{00}}, \quad J = \frac{m_{01}}{m_{00}} \quad (5)$$

where  $p(i, j)$  is the intensity function representing the image,  $M, N$  stand for the size of the image with the extracted eye-cup.

$I_1, I_2, I_5, I_7, I_{14}$  are compound invariant moments defined as:

$$I_1 = \mu_{20}\mu_{02} - \mu_{11}^2 \quad (6)$$

$$I_2 = (\mu_{30}\mu_{03} - \mu_{21}\mu_{12})^2 - 4(\mu_{30}\mu_{12} - \mu_{21}^2)(\mu_{21}\mu_{03} - \mu_{12}^2) \quad (7)$$

$$I_5 = \mu_{20} + \mu_{02} \quad (8)$$

$$I_7 = (\mu_{30} - 3\mu_{12})^2 - (\mu_{03} - 3\mu_{21})^2 \quad (9)$$

$$I_{14} = \frac{I_4}{\mu_{00}I_2} \quad (10)$$

where

$$\begin{aligned} I_4 = & \mu_{30}^2\mu_{02}^3 - 6\mu_{30}\mu_{21}\mu_{11}\mu_{02}^2 - 6\mu_{30}\mu_{12}\mu_{02}(\mu_{11}^2 - \mu_{20}\mu_{02}) + \\ & + \mu_{30}\mu_{03}(6\mu_{20}\mu_{11}\mu_{02} - 8\mu_{11}^3) + 9\mu_{21}^2\mu_{20}\mu_{02}^2 - 18\mu_{21}\mu_{12}\mu_{20}\mu_{11}\mu_{02} + \\ & + 6\mu_{21}\mu_{03}\mu_{20}(2\mu_{11}^2 - \mu_{20}\mu_{02}) + 9\mu_{12}^2\mu_{20}^2\mu_{02} - 6\mu_{12}\mu_{03}\mu_{11}\mu_{20}^2 + \mu_{03}^2\mu_{20}^3 \end{aligned} \quad (11)$$

Circular coefficient  $R_{c2}$  is calculated as ratio of object perimeter to  $\pi$ . Area to perimeter coefficient  $W_{sl}$  is given by ratio of object area to object perimeter coefficient.

### 3.3 Classification of fundus eye images

The method makes use of the neural network classifier (8-4-2 multilayer perceptron [9]) with standard backpropagation learning rule. For comparison we also tested kNN and rule-based classifiers.

## 4 Results

The new method has been applied into 50 fundus eye images of patients with glaucoma and 50 fundus eye images of normal patients which were previously examined by conventional methods (perimetry, slit lamp with Volk lens). The cup is automatically segmented in the fundus images obtained by Canon CF-60Uvi fundus camera. Next, for the segmented cup the whole set of 30 geometric features is computed. The obtained set of labelled feature vectors is divided into 3 parts: one training and two testing sets. The training set and one testing set are used by genetic algorithms for suboptimal feature vector calculation. On the second testing set of images the suboptimal feature vectors are calculated and pushed into classifier which assigns it a class: normal or glaucomatous. Classifier performance is tested by k-fold cross validation method and gives the following results: neural networks classifier with sensitivity of 90 % and specificity of 86%, KNN classifier with sensitivity of 65% and specificity of 72% and rule-based classifier with sensitivity of 58% and specificity of 64%.

## 5 Conclusion

Our method proves that shape of the cup and its numerical characteristics correlate with progress of glaucoma. It also shows that by reducing irrelevant information and using only selected features the classifier performance can be improved significantly which is very important for application supporting glaucoma diagnosing. It is expected that the new method, after clinical tests would support glaucoma diagnosis based on digital fundus eye images obtained from fundus-camera. Improvements of the method are expected by better segmentation method based for example on fuzzy clustering.

## References

1. Kanski J et al.: Glaucoma: A color manual of diagnosis and treatment. Butterworth-Heinemann, 1996.
2. Goh K.G, Hsu W, Lee ML et al.: ADRIS: an Automatic Diabetic Retinal Image Screening system. In: K. J. Cios (Ed.): Medical Data Mining and Knowledge Discovery, 181–210, Springer, New York, 2000.
3. Morris DT, Donnison C: Identifying the Neuroretinal Rim Boundary Using Dynamic Contours. *Image and Vision Computing*, 17: 169–174, 1999.
4. Osareh A, Mirmehdi M, Thomas B et al.: Classification and localisation of diabetic related eye disease. In: A. Heyden et al. (Eds.): LNCS 2353: 502–516, 2002.
5. Gonzalez RC, Woods RE: Digital image processing. Prentice-Hall, 2002.
6. Chaudhuri S, Chatterjee S, Katz N et al.: Detection of Blood Vessels in Retinal Images Using Two-Dimensional Matched Filters. *IEEE Trans Med Imaging*, 8(3): 263–269, 1989.
7. Trier ØD, Jain AK, Taxt T: Feature extraction methods for character recognition—A survey. *Pattern Recognition*, 29(4): 641–662, 1996.
8. Arabas J: Lectures on genetic algorithms. WNT, Warsaw, 2001.
9. Bishop CM: Neural networks for pattern recognition. Clarendon Press, Oxford, 1995.